

Mammography Education, Inc.

2011

BREAST SEMINAR SERIES

LÁSZLÓ TABÁR, M.D., F.A.C.R (Hon) Course Director
Professor of Radiology

ULRICH BICK, M.D.
Professor of Radiology

ALFONSO FRIGERIO, M.D.

present

**MULTIMODALITY DETECTION and
DIAGNOSIS of BREAST DISEASES**

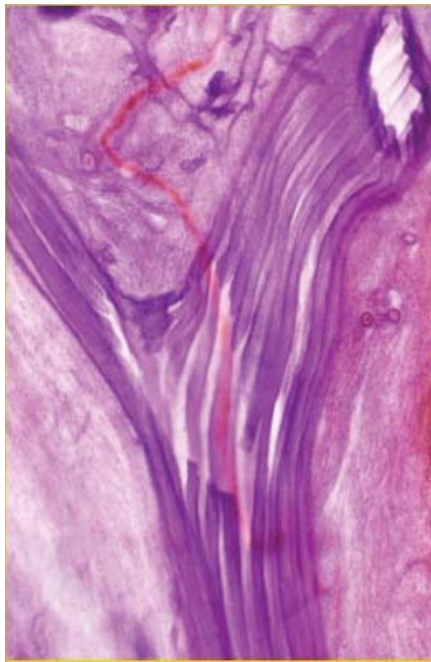
Rome, Italy
Radisson Blu
Dec 5-7, 2011

Designed for:

**Radiologists • Surgeons • Pathologists
Gynecologists • Radiology Technologists**

Implications of mammography, MRI, breast ultrasound and interventional methods in radiological and surgical practice

This course provides extensive knowledge about diagnostic breast imaging, differential diagnosis of breast diseases, surgical management and newest diagnostic technologies.



3D image of a milk duct



17 HOURS OF CATEGORY I CME CREDITS



2011
BREAST SEMINAR SERIES
Multimodality Detection and
Diagnosis of Breast Diseases

László Tabár, M.D.,
F.A.C.R.(Hon)
*Professor of Radiology
Course Director*

FACULTY MEMBERS



László Tabár, M.D., F.A.C.R. (Hon).
Course Director
*Professor of Radiology, University of
Uppsala School of Medicine, Sweden
Department of Mammography,
Falun Central Hospital, Falun, Sweden*



Ulrich Bick, M.D., MRI Expert
*Professor of Radiology, Charité -
Universitätsmedizin
Department of Radiology,
Charite Campus Mitte
Berlin, Germany*



Alfonso Frigerio, M.D.

*Regional Reference Center for
Breast Cancer Screening,
CPO-Piemonte,
S. Giovanni Battista Hospital, Torino, Italy*



2011
BREAST SEMINAR SERIES
Multimodality Detection and
Diagnosis of Breast Diseases

László Tabár, M.D.,
F.A.C.R.(Hon)
*Professor of Radiology
Course Director*



Mammography Education, Inc. is accredited by the Accreditation Council for Continuing Medical Education to sponsor continuing medical education for physicians. Mammography Education, Inc. designed these medical education activities for a maximum of **17 credit hours in Category I** of the Physicians' Recognition Award of the American Medical Association.

Each physician should claim only those hours of credit that he / she actually spent in the educational activity.

This course also applies for the Italian System of CME credits (ECM). Italian physicians may claim only those hours of credit that she/he actually spent in the educational activity. The credits can be claimed through our Italian agent KONICAB (see below)

Italian Scientific Organizing Committee

Dott. Alfonso Frigerio, M.D., Ospedale S. Giovanni Battista, **Torino**, Italy
e-mail: alfonso.frigerio@cpo.it

CREDITS

We would like to thank the sponsors for their support of the teaching seminars of Mammography Education, Inc (list of vendors will be presented at the beginning of the course)

Information on hotel reservations *and* information for the Italian attendees

Ms. Paola Garuffi, **Konicab Congressi srl** - Bologna, Italy. Phone: (0039) - 051 - 385 328. Fax: (0039) 051-311 350.

English with simultaneous translation to **Italian**.



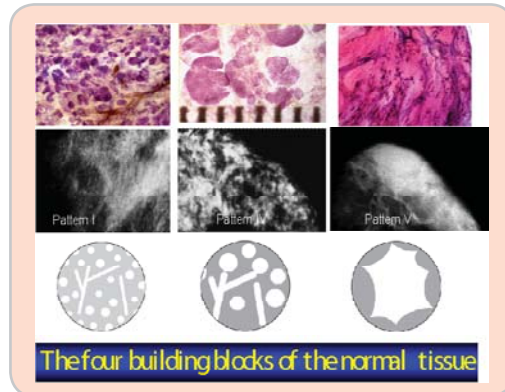
1st DAY Morning lectures between 8:30 AM and 12:00

8:30 INTRODUCTION FOLLOWED BY DIDACTIC LECTURES COVERING:

A NEW ERA in the DIAGNOSIS and TREATMENT of BREAST CANCER.
THE ISSUE of UNI- and MULTIFOCALITY - CLINICAL IMPLICATIONS

THE BASIS FOR EFFICIENT INTERPRETATION OF THE MAMMOGRAPHIC IMAGE

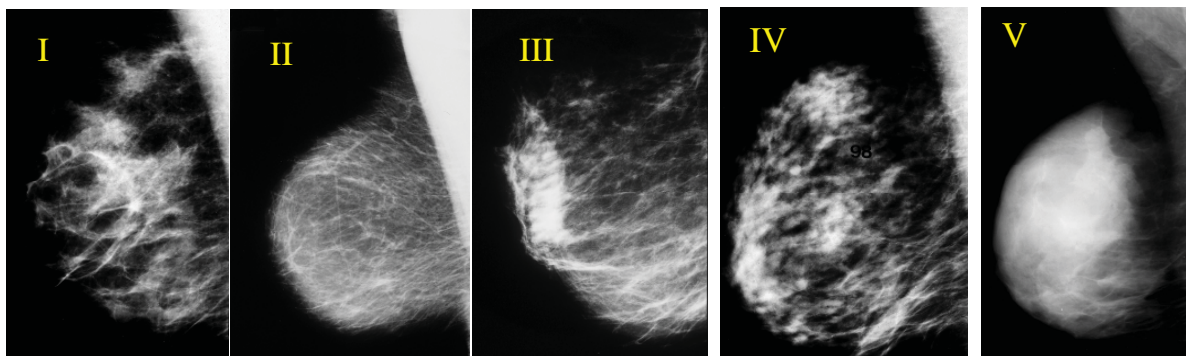
- Correlative 3-dimensional, subgross anatomy and mammography of the normal breast
- **The problem:** The variable appearance of the normal mammogram.
- **The solution:** classification into structural subtypes, mammographic parenchymal patterns, based on 3D/subgross histologic-mammographic correlation.
- **Result:** Increased confidence in reading a mammogram and finding subtle perceptual abnormalities
- The dynamic change of mammographic patterns and its application in clinical practice



Breaks at 10:00
and
at 11:00 AM

MAMMOGRAPHIC PARENCHYMAL PATTERNS

- Practical implication, problems and solutions. Mammographic patterns and the risk of developing breast cancer. Understanding the mammograms of dense breasts.



12:00 Lunch



1st DAY Afternoon lectures between 1:30 AM and 4:30

1:30 THE LECTURE SERIES WILL COVER THE FOLLOWING TOPICS:

DIDACTIC WORKUP OF ASYMMETRIC DENSITIES ON THE MAMMOGRAM

- Normal breast tissue (*specific* asymmetric densities) / focal fibrosis / fibroadenolipoma
- *Non-specific* asymmetric densities: PASH, diabetic mastopathy, granulomatous mastitis
- Asymmetric densities with architectural distortion

- Definite pathologic lesions:

BENIGN CIRCULAR / OVAL SHAPED LESIONS WITHOUT ASSOCIATED CALCIFICATIONS

- Cysts, fibroadenoma, papilloma, pyllodes tumors, galactocele, abscess
- Histology correlation with mammograms, MRI and clinical findings of benign lesions

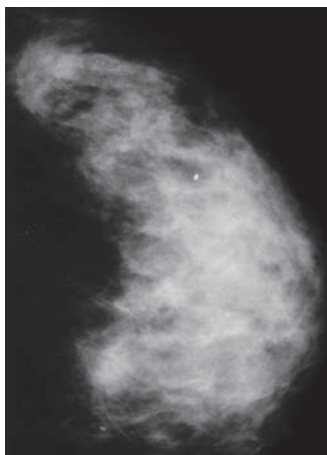
MALIGNANT CIRCULAR / OVAL LESIONS: clinical presentation, histology, mammographic-ultrasound-MRI appearance and long-term outcome

- **Medullary cancer:** one of the fastest growing breast cancers
- **Mucinous and papillary cancers:** unusual and special forms
- **Poorly differentiated invasive ductal carcinoma**
- **Metastasis to the breast**

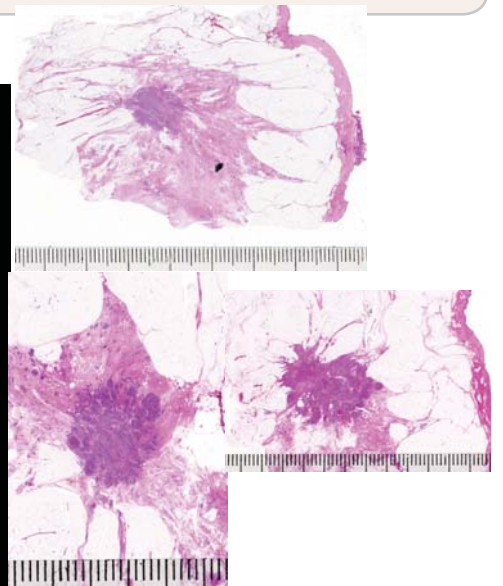
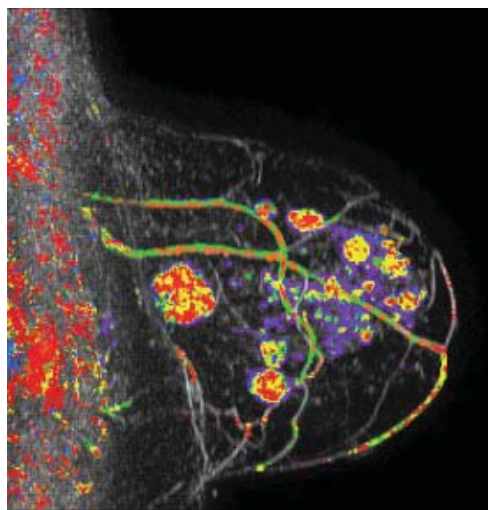
**Breaks at 2:00
and
at 3:00 PM**

BREAST MRI - THE BASICS - [U Bick](#)

BREAST MRI AS PART OF ASSESSMENT IN MAMMOGRAPHY SCREENING - [U Bick](#)



4:30 End of Day 1





2nd DAY

Morning lectures between 8:30 AM and 12:00 PM

8:30 HIGH RISK MULTIMODALITY SCREENING - U Bick

HOW TO FIND THE INVASIVE BREAST CANCER WHEN IT IS STILL SMALL. SCREENING COMBINED WITH AN ANALYTICAL APPROACH FOR THE DIFFERENTIAL DIAGNOSIS OF STELLATE / SPICULATED LESIONS - L Tabar

- A systematic method for viewing mammograms. Areas on the mammogram where most breast cancers will be found. Viewing dense breasts. Viewing relatively easy-to-read breasts

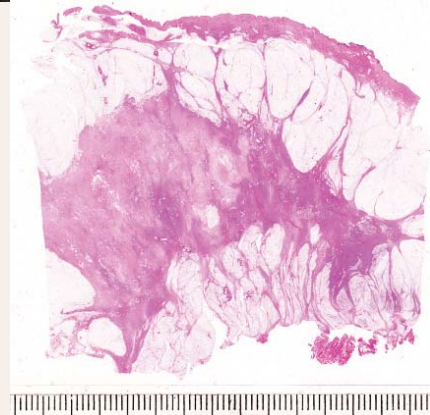
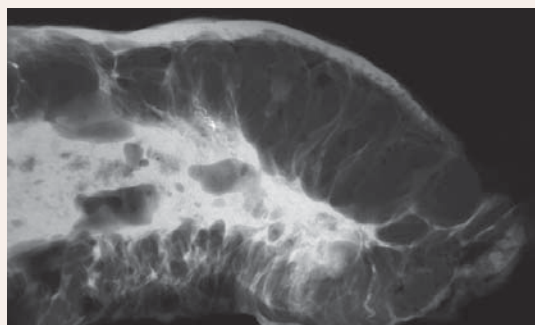
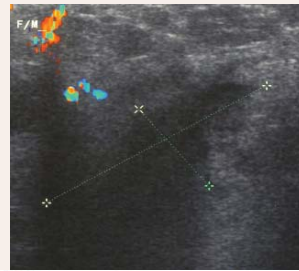
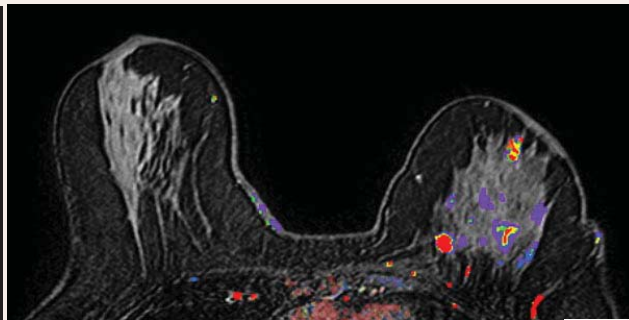
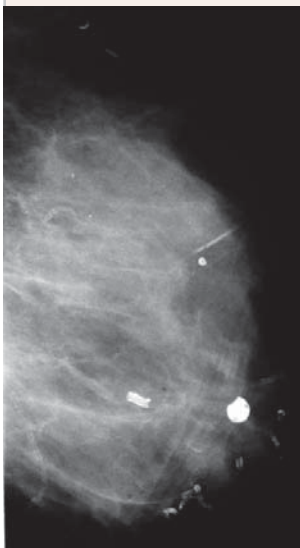
PRACTICE IN PERCEPTION OF SUBTLE, NON-CALCIFIED CANCERS

The role of hand-held ultrasound / 3D automated ultrasound / MRI in the detection and workup of the findings. The multimodality approach

- *Malignant stellate lesions*: clinical presentation, histology, mammographic/ MRI/ ultrasound appearance and outcome:

Breaks at 10:00
and
at 11:00 AM

- **invasive ductal carcinoma**, not otherwise specified (NOS): the most frequently occurring carcinoma. Multimodality case demonstrations
- **tubular carcinoma**: the stellate tumor with the best outcome
- sonographic and MRI correlation with the mammogram



Multimodality workup of a huge invasive lobular carcinoma

12:00 Lunch



2nd DAY

Afternoon lectures between 1:30 PM and 4:30 PM

1:30 SCREENING COMBINED WITH AN ANALYTICAL APPROACH FOR THE DIFFERENTIAL DIAGNOSIS OF STELLATE/SPICULATED LESIONS - CONT. [L Tabar](#)

BENIGN RADIATING STRUCTURES on the mammogram

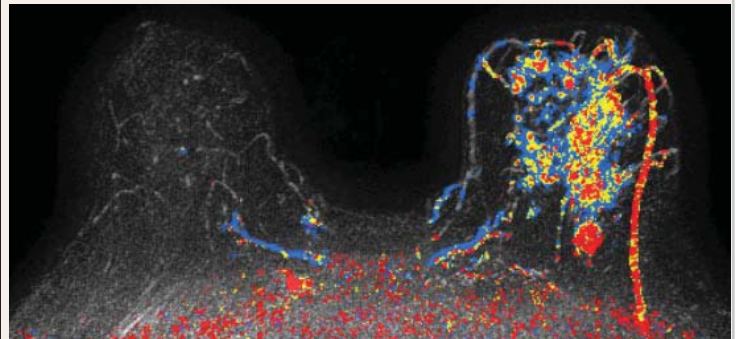
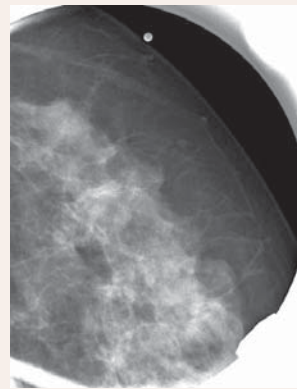
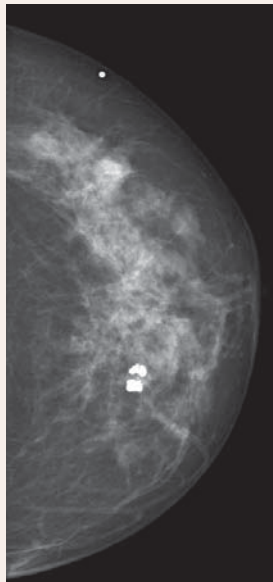
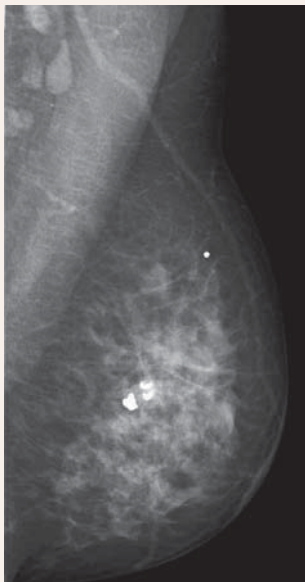
- **Radial scar**. Traumatic (postsurgical) **scar / fat necrosis / granular cell tumor**
- Indications and contraindications of using preoperative percutaneous biopsy techniques

PRACTICE IN PERCEPTION OF SUBTLE, NON-CALCIFIED CANCERS.

The role of hand-held ultrasound / 3D automated ultrasound / MRI in the detection and workup of the findings. The multimodality approach.

- *Malignant stellate lesions*: clinical presentation, histology, mammographic appearance and outcome:
 - **invasive lobular carcinoma**: the most deceptive and frequently missed cancer of the breast. The value of ultrasound and MRI in finding and diagnosis invasive lobular cancer subtypes. Case demonstrations

Breaks at 2:00
and
at 3:00 PM



3:30 DEMONSTRATION OF SPECIAL TEACHING CASES - A. FRIGERIO

4:15 ART HISTORY LECTURE: MICHELANGELO AND RAPHAEL two giants collide - A FRIGERIO

5:00 PM End of Day 2



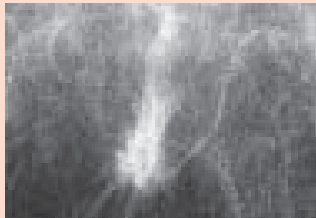3rd DAY Morning lectures between 8:30 AM and 12:00 PM

8:00 THE DIDACTIC LECTURE SERIES WILL COVER THE FOLLOWING TOPICS:

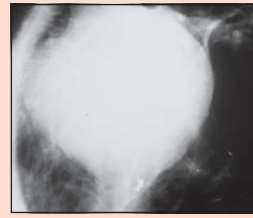
DESCRIPTION OF THE MAMMOGRAPHIC SIGNS OF *IN SITU* BREAST CANCER

- Every fourth CIS case is detected by mammographic signs other than calcifications
- **Special forms of *in situ* carcinoma**
 - architectural distortion
 - dominant mass
 - cases detected by galactographic examination

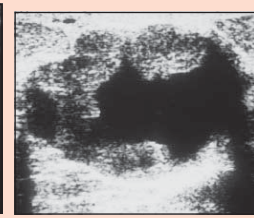
Breaks at 10:00
and
at 11:00 AM



Architectural distortion, *in situ* carcinoma



Dominant mass, *in situ* carcinoma

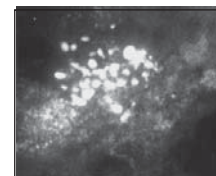
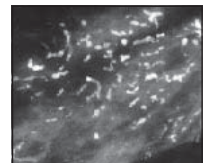


SCHEME FOR THE ANALYSIS OF MAMMOGRAPHIC CALCIFICATIONS

- Determining the **anatomic cavity** occupied by the calcifications ("location")
- Analyzing the **shape/density/size** of the calcifications
- Understanding the benign and malignant **pathologic processes** leading to the formation of calcifications within the ducts and within the TDLU
- Diagnosis and differential diagnosis of **calcifications localized within the ducts** using multimodality approach, including MRI
- The morphologic analysis of calcifications localized within the TDLUs. Diagnosis and differential diagnosis of **crushed stone-like / pleomorphic calcifications**

BENIGN TYPE CALCIFICATIONS IN HYPERPLASTIC BREAST CHANGES, CAUSING DIFFERENTIAL DIAGNOSTIC PROBLEMS

- **Weddellites, powdery / cotton ball-like calcifications**



12:00 Lunch



3rd DAY Afternoon lectures between 1:00 PM and 4:00 PM

1:00 THE DIDACTIC LECTURE SERIES WILL COVER THE FOLLOWING TOPICS:

SKIPPING STONE-LIKE CALCIFICATIONS ON THE MAMMOGRAM

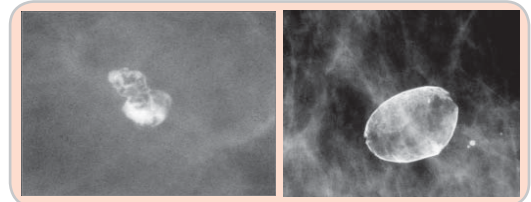
NOT DISCERNABLE CALCIFICATIONS WITHIN THE TDLU (cotton ball-like calcifications)

- Sclerosing adenosis vs Grade 1 *in situ* carcinoma

CALCIFICATIONS LOCALIZED OUTSIDE THE GLANDULAR TISSUE

- Interactive evaluation and differential diagnosis of benign versus malignant type calcifications by course participants
- Assigning probability of malignancy to the various calcification subtypes
- Indications and contraindications for preoperative needle biopsy of calcifications
- Short-term follow up of calcifications: pitfalls
- The obviously benign type calcifications.

**Breaks at 2:00
and
at 3:00 PM**



LYMPHEDEMA OF THE BREAST - A DIFFERENTIAL DIAGNOSTIC CHALLENGE

- Didactic approach to the differential diagnosis of diseases leading to lymph stasis of the breast
- Regular follow-up of patients after breast cancer surgery. Postoperative and postirradiative changes with time

DISCUSSION AND CLOSING REMARKS

4:00 End of the course



2011
BREAST SEMINAR SERIES
Multimodality Detection and
Diagnosis of Breast Diseases

László Tabár, M.D.,
F.A.C.R.(Hon)
*Professor of Radiology
Course Director*

For more information and
registration please contact:

Mammography Education, Inc.
4429 E. Spur Drive
CAVE CREEK, AZ 85331, USA

Phone: (480) 419 0227

Fax: (480) 419 0219

e-mail: info@mammographyed.com


Internet: www@mammographyed.com

THE SCHEDULE IS SUBJECT TO CHANGE WITHOUT NOTICE AND
DOES NOT REPRESENT A COMMITMENT ON THE PART OF M.E.I.
ALL RIGHTS RESERVED INCLUDING THE RIGHT OF REPRODUCTION
IN WHOLE OR IN PART OF ANY FORM

VISIT US ON THE INTERNET:

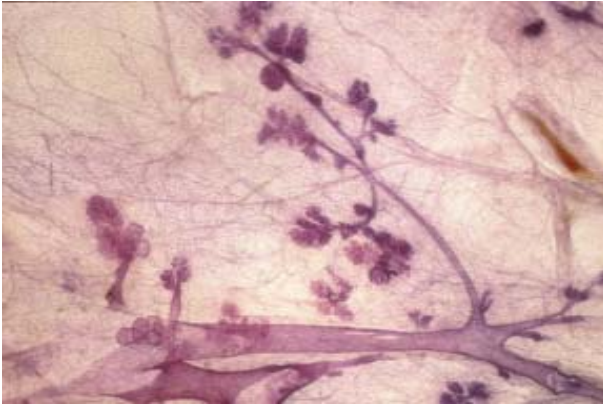
[HTTP://WWW.MAMMOGRAPHYED.COM](http://WWW.MAMMOGRAPHYED.COM)

COPYRIGHT ©

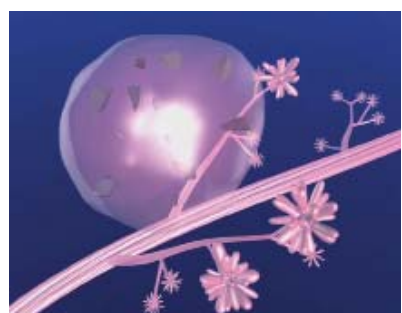
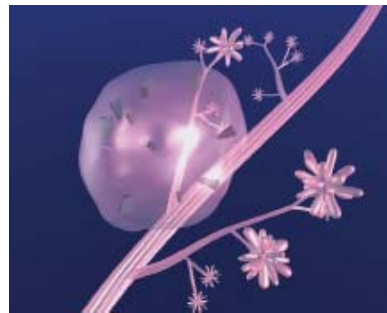
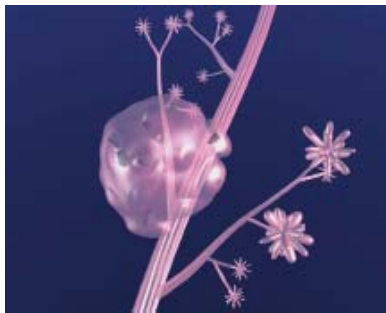
Images from the non-profit Tabar Foundation for Research and Education for Breast Cancer

www.tabarfoundation.org



3-D histologic image of TDLUs



Computer simulation images of the development of Grade 2 *in situ* carcinoma within the TDLU. The lobule becomes gradually distended and deformed. Calcifications are formed within the necrotic debris and are seen on the mammogram as **crushed stone-like calcifications**.

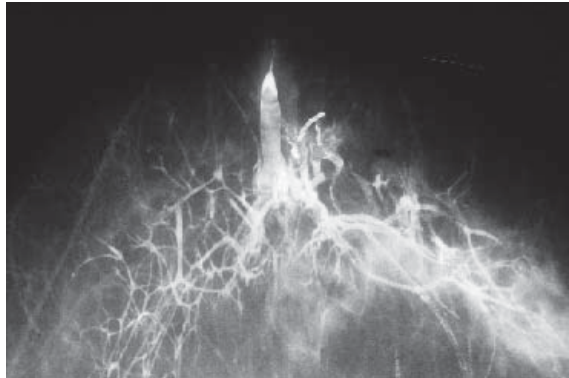


2011
BREAST SEMINAR SERIES
Multimodality Detection and
Diagnosis of Breast Diseases

László Tabár, M.D.,
F.A.C.R.(Hon)
*Professor of Radiology
Course Director*



Protea (sugar bush). Cape Town, South Africa



Galactogram of a large lobe occupying both the medial and lateral half of the breast



Photographs from Kirstenbosch botanical garden, Cape Town, South Africa